



The common diseases of freshwater ornamental fishes and the treatments applied by local fish owners in Puerto Princesa City, Palawan, Philippines

Niño Jess Mar F. Mecha • Maria Mojena Gonzales-Plasus

College of Fisheries and Aquatic Sciences, Western Philippines University, Puerto Princesa City, 5300, Philippines

Correspondence

Niño Jess Mar F. Mecha; College of Fisheries and Aquatic Sciences, Western Philippines University, Puerto Princesa City, 5300, Philippines

 njmf19mecha@gmail.com

Manuscript history

Received 27 August 2022 | Accepted 7 December 2022 | Published online 21 April 2023

Citation

Mecha NJMF, Gonzales-Plasus MM (2023) The common diseases of freshwater ornamental fishes and the treatments applied by local fish owners in Puerto Princesa City, Palawan, Philippines. *Journal of Fisheries* 11(1): 111205. DOI: 10.17017/j.fish.485

Abstract

The demand for freshwater ornamental fish as anti-stress pets and a source of livelihood had become popular in Puerto Princesa City (PPC), Palawan during the surge of COVID-19. However, the occurrence of many health-related issues become a major problem due to a lack of experience and knowledge of some fish owners engaged in freshwater ornamental fish keeping and breeding methods. This study was conducted on 13 local fish owners to determine the common diseases in freshwater ornamental fishes, affected species and their life stages and the treatments and preventive measures. A total of 19 diseases were recorded infecting the freshwater ornamental fishes in PPC. White-spot or ich disease was the most prominent disease, followed by tail and fin rot. Juvenile and adult of goldfish (*Carassius auratus*), Siamese fighting fish (*Betta splendens*) and guppy (*Poecilia reticulata*) were the most infected fishes, observed by 1 (7.7%) to 5 (38.5%) fish hobbyist. The salt bath was the most common treatment applied. Measures to increase the awareness of local fish hobbyist in terms of fish handling, breeding and health management is highly suggested to continuously improve and expand this developing fishery in Palawan as a source of income and pet companion.

Keywords: aquarium fish; external symptoms; fish disease; ornamental fish; salt bath; treatments

1 | INTRODUCTION

Globally, freshwater ornamental fish is the largest sector in the ornamental fish industry (Livengood and Chapman 2007; Muyot *et al.* 2019). Due to its numerous benefits such as mental health and good social impact (Clements *et al.* 2019) and source of income (Nanayakkara *et al.* 2021; Saba *et al.* 2021), there are millions of enthusiasts engaged in this sector (Lipton 2006). According to Faruk *et al.* (2012), the global trade is based on more than 4000 species of freshwater ornamental fishes. However, the continuous global demand for freshwater ornamental fish resulted in the depletion of its wild populations (Sanil and Vijayan 2008). In recent years, 90% of freshwater orna-

mental fishes involved in global trade were subjected to intensive culture and breeding methods by many freshwater ornamental fish breeders (Sanil and Vijayan 2008; Bassleer 2017). Unfortunately, many breeders lack experience and knowledge of proper breeding methods resulting in the occurrence of various diseases and health-related problems (Rao *et al.* 2013; Magada and Mercy 2016; Bassleer 2017).

Like human diseases, fish diseases are also categorised as infectious and non-infectious (Magada and Mercy 2016; Nair *et al.* 2020). Diseases under protozoan, parasitic, bacterial, viral or fungal are categorised as infectious diseases (Magada and Mercy 2016; Cardoso *et al.* 2019),

while diseases due to environmental conditions, poor nutrition and genetics are categorised as non-infectious diseases (Sanil and Vijayan 2008; Magada and Mercy 2016). They are also categorised based on what part of the fish they infect (Lipton 2006; Magada and Mercy 2016). Diseases infecting the external part of fish are called external diseases and they are visible to the naked eye even without laboratory equipment (Lipton 2006; Miles 2019). Diseases that infect the internal part of fish and are not visible to the naked eye are called internal diseases (Roberts 2010; Cardoso *et al.* 2019; Miles 2019). However, some diseases have unclear etiology or combinations of pathogen infestation, environmental conditions and genetics, and they are called multifactorial diseases (Magada and Mercy 2016; Miles 2019). Some internal and multifactorial diseases have external symptoms (e.g. bloat and spinal deformities) that can be detected by the naked eyes only (Roberts 2010; Magada and Mercy 2016; Cardoso *et al.* 2019; Miles 2019). Many factors (e.g. stressful environment, poor breeding conditions, inadequate transportation, stocking density and poor nutrition) can weaken the immune system of fish making them susceptible to any disease attack (Watson and Shireman 2002; Magada and Mercy 2016; Bassleer 2017; Walczak *et al.* 2017). Diseases can lead to a significant loss of investment and anxiety the fish owners (Magada and Mercy 2016), a breach of biosecurity of the ornamental fish industry (OATA 2006), as well as a risk to the health of fish owners from zoonotic diseases (Cardoso *et al.* 2019).

Treatments employed in diseases of freshwater ornamental fishes varied from the use of table salt, water exchange and application of commercial drugs (Magada and Mercy 2016; Cardoso *et al.* 2019). However, the lack of knowledge and appropriate training on fish health management of various fish owners resulted in the use of treatment that can worsen the condition of fish and lead to death of fish (Magada and Mercy 2016). Further, the use of water treatments can be a threat to the health of fish when not properly used and applied because most water conditioner contains carcinogenic components, (Sudova *et al.* 2007; Roberts-Sweeney 2016). Moreover, improper handling of infected fish (e.g. improper disposal of the diseased fish within the body of water) can cause disease transmission which threatened the biosecurity of the nearby aquatic environment (Miller-Morgan and Heidel 2010).

In Puerto Princesa City, Palawan, ornamental fish are slowly gaining popularity among small-scale producers; however, there is limited baseline information regarding this sector (Plasus *et al.* 2022). The local fish owners in Palawan are promoting the production of locally produced ornamental fish and venturing to improve the quality of fish involved but these are being challenged by the presence of diseases coupled with the lack of knowledge in breeding methods and fish health manage-

ment. Hence, this study investigated the health-related problems of freshwater ornamental fish. The finding would provide relevant information for the improvement of this sector particularly the knowledge of fish owners involved. Specifically, this study aimed to determine the common diseases with external symptoms infecting the freshwater ornamental fishes in Palawan, the species and life stages of infected ornamental fishes and treatments or preventive measures applied by the local fish owners in Palawan.

2 | METHODOLOGY

2.1 Study area

The study was conducted in Puerto Princesa City, Palawan, Philippines (Figure 1). The location was identified with a high population of local fish owners engaged in freshwater ornamental fish activities (Plasus *et al.* 2022).

2.2 Data collection and respondents

Since there was a restriction during the conduct of the study due to the surge of the COVID-19 pandemic, the data was gathered through an online survey using the Google form questionnaire. The Google form had three sections; first, the information (see Supplementary Information) and photos of 39 various diseases with external symptoms. These were extracted from various literature that deals with diseases in freshwater ornamental fishes (e.g. Lewbart 2001; Lipton 2006; Illes 2007; Alderton 2008; Sanil and Vijayan 2008; Roberts *et al.* 2009; Roberts 2010; Sharma *et al.* 2012; Rao *et al.* 2013; Magada and Mercy 2016; Cardoso *et al.* 2019; Miles 2019). Second, information on the species and life stages of fishes infected by various diseases with external symptoms. Lastly, the treatments and preventive measures employed by the respondents in treating the diseases. Each section has multiple choices answers for the respondents to select.

The Google form with consent form was posted on 17 January 2021 to a Facebook group named Palawan Local Fish Hobbyists and Aquatic Plant Keepers and available until 23 January 2021. This group was purposively selected as it is the only available social media group with local fish owners in Palawan during the conduct of the study with more than 70 members engaged in freshwater ornamental fish activities in Puerto Princesa City. However, only 13 respondents participated in the survey (Table 1). These respondents were composed of suppliers / producers, hobbyists and pet shop owners. Most of the respondents were in fish keeping for two years or more (Table 1). Photos of diseases infecting the fish from various respondents were also solicited whenever possible.

2.3 Data analysis

Data collected from Google forms were transferred and analysed using Microsoft Excel for frequency and percentage analysis.

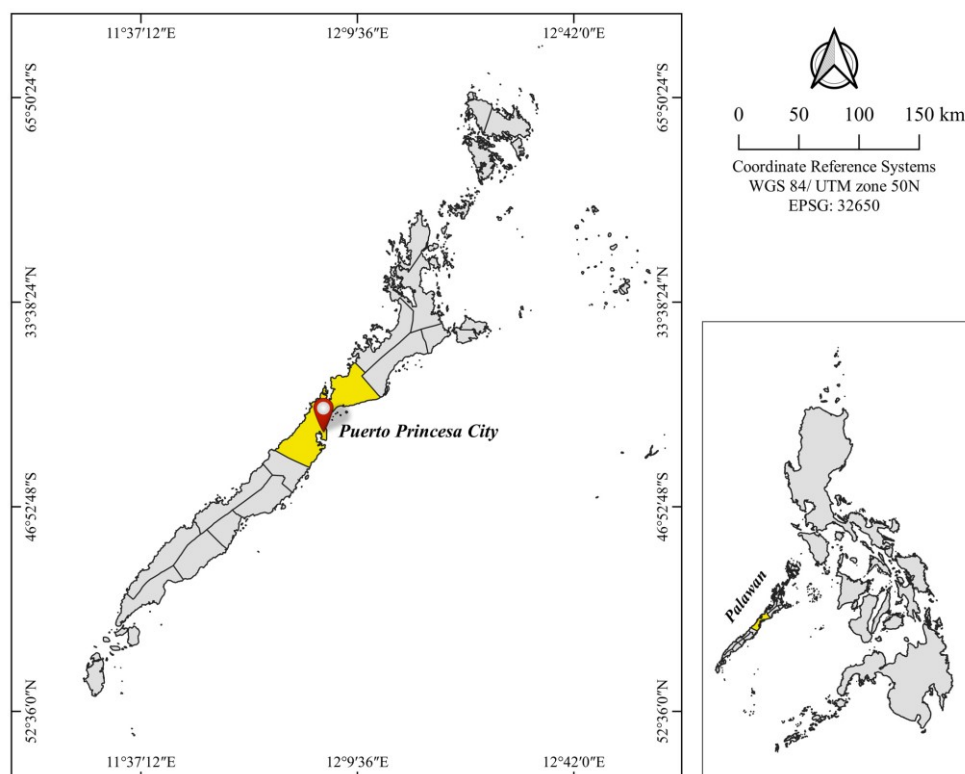


FIGURE 1 Location of Puerto Princesa City in the province of Palawan, Philippines.

TABLE 1 The demographic profile of all respondents from Puerto Princesa City of Palawan participated in the online survey. ($n = 13$; data presented as frequency (F) and percentage (%)).

Variable		F (%)
Sex	Male	7 (53.85)
	Female	6 (46.15)
Age (year)	18-30	7 (53.85)
	31-50	6 (46.15)
Civil status	Single	8 (61.54)
	Married	5 (38.46)
Years in the ornamental fish industry (experience)	1 year	1 (7.69)
	2 years	8 (61.54)
	4 years	2 (15.38)
	10 years above	2 (15.38)
Source of supply	Local	9 (69.23)
	National	1 (7.69)
	Both	3 (23.08)
Landing port	Airport	2 (15.38)
	Seaport	0 (0.00)
	Both	2 (15.38)
	None (for local source fish)	9 (69.23)

3 | RESULTS AND DISCUSSION

3.1 Diseases with external symptoms

A total of 19 out of 39 diseases with external symptoms were identified by 13 respondents infecting their fresh-

water ornamental fishes (Figure 2). White spot disease or Ich, a protozoan disease, was the most prevalent infecting the fishes of all respondents (Figures 2 and 3). This was followed by tail and fin rot, a bacterial disease, infecting the fish of 11 respondents (Figure 2).

The presence of white spot disease or Ich in the fish individuals of 13 respondents indicates that this particular disease is common in ornamental fish. According to Rao *et al.* (2013) and Miles (2019), ich is a common parasite in fish that comes from the introduction of fish or plants carrying the cysts of the parasite. In addition, Sanil and Vijayan (2008) described the ich as a parasite with a lack of host specificity; therefore, it can infect any fish species, making it the most destructive fish parasite in ornamental fishes. Aquarium fishes, in general, are susceptible to various diseases due to controlled environmental conditions which were intensified by the hobbyist's lack of knowledge in proper fish keeping which resulted in poor water quality, high stocking densities, poor nutrition and inferior breed quality (Rao *et al.* 2013; Magada and Mercy 2016; Cardosa *et al.* 2019). These conditions lead to a subsequent weakening of immunity, deficiencies and many health-related problems in fish that allows various pathogens which are often a natural part of the environment to infect (Miles 2019). However, these health-related problems could be controlled if the fish owners have enough knowledge in employing standard fish-keeping and management procedures (Magada and Mercy 2016).

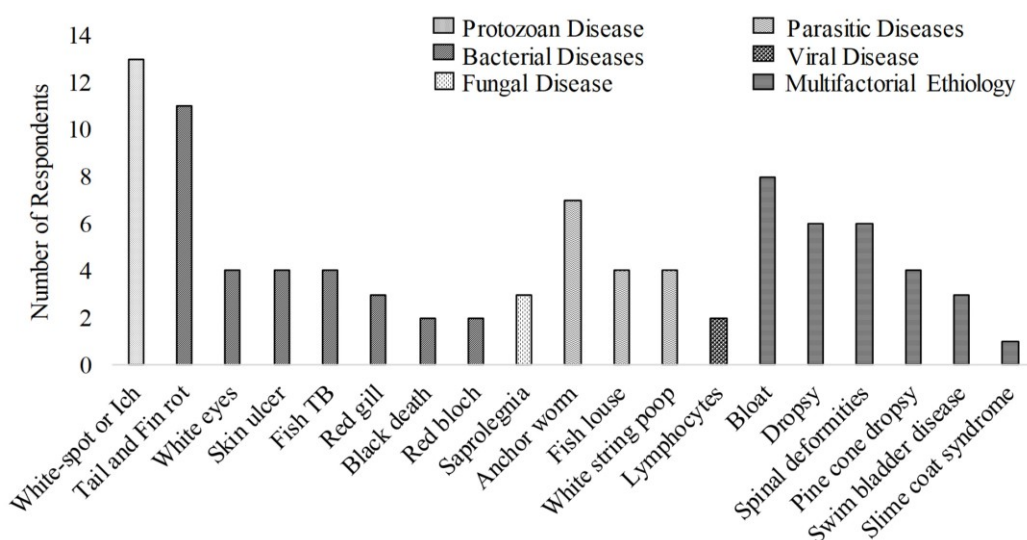


FIGURE 2 List of diseases with external symptoms identified by various respondents infecting their freshwater ornamental fishes. Diseases were selected multiple times.



FIGURE 3 Some of the diseases identified by four respondents that infect their freshwater ornamental fish. A and B, a goldfish and molly fish with suspected haemorrhagic septicemia or red bloch; C, a goldfish with suspected white-spot or ich; and D, a danio fish with suspected spinal deformity. Photo credit: B. Nolie, LE Rodriguez, ME Aragon and FS Tolentino respectively.

On the other hand, one of the alarming information gathered from the survey was the presence of a parasitic disease in the fish bought by one of the respondents from a pet shop in Puerto Princesa City. The abovementioned condition indicates that even the pet shop owner is not knowledgeable about addressing this particular disease and the infected fish is still available for sale. This situation further shows that transmission of diseases can occur between seller and hobbyist which can cause anxiety to the side of the buyer instead of relaxation. An essential

component of a thriving ornamental culture or aquarium system is the implementation of fish health management programs that aims at preventing the spread of diseases (Rao *et al.* 2013; Magada and Mercy 2016).

3.2 Species and life stages of infected freshwater ornamental fishes

The goldfish (*Carassius auratus*), Siamese fighting fish (*Betta splendens*) and guppy (*Poecilia reticulata*) were the most infected of various diseases encountered by 1 (07.69%) to 5 (38.46%) respondent/s since they were the most popular fish pet candidates for aquariums (Table 2). For example, Muyot *et al.* (2019) reported that goldfish and guppy are the top freshwater ornamental fish species produced in the Philippines. In Palawan, the most popular species are the Siamese fighting fish, guppy, goldfish and molly (Plasus *et al.* 2022). These species are also popular in other parts of the world (Galib and Mohsin 2010; Galib *et al.* 2013).

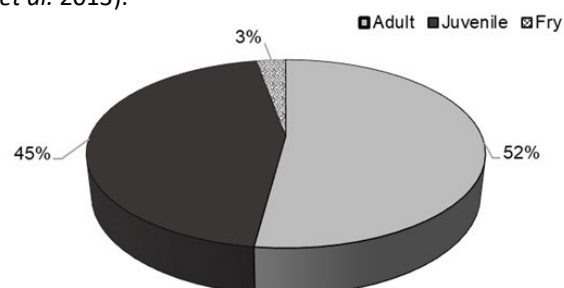


FIGURE 4 The percentage of freshwater ornamental fish life stages infected by various diseases.

The life stages of ornamental fishes infected with various diseases were mostly juvenile and adult (Figure 4; Table 2). White spot or ich, the most infectious disease was found by 5 respondents (38.5%) infecting juvenile and adult goldfish. The tail and fin rot was observed by 3 (23.1%) and 4 (30.8%) respondents in juvenile and adult goldfish and Siamese fighting fish respectively (Table 2).

This information agreed with the findings of Sharma *et al.* (2012) on the infestation of tail and fin rot disease since the early life stages of fish in captivity have low tolerance against diseases.

TABLE 2 Species and life stages of freshwater ornamental fish, the observed diseases and the number of respondents with infected fish. Data of respondents were presented as frequency (*F*) and percentage (%). (*) asterisk in fish species column indicates a newly listed species in Palawan (Plasus *et al.* 2022). (**) double asterisk means the same respondent. NDA, No data available.

Fish species	Observed diseases	Respondents and life stages	
		Juvenile	Adult
Siamese fighting fish (<i>Betta splendens</i>)	Lymphocytes	2 (15.38)	NDA
	Tail and fin rot	**3 (23.08)	**3 (23.08)
	White eyes	NDA	2 (15.38)
	Saprolegnia	2 (15.38)	1 (07.69)
	White-spot or ich	**1 (07.69)	**1 (07.69)
	Dropsy	2 (15.38)	NDA
	Fish TB	**1 (07.69)	**1 (07.69)
	Red gill	NDA	3 (23.08)
	White string poop	NDA	1 (07.69)
	Bloat	**1 (07.69)	**1 (07.69)
	Slime coat syndrome	NDA	1 (07.69)
*Discus (<i>Symphysodon</i> sp.)	Black death	2 (15.38)	NDA
Flowerhorn (<i>Vieja synspilum</i>)	Fish TB	**1 (07.69)	**1 (07.69)
	White-spot or ich	**1 (07.69)	**1 (07.69)
	White string poop	NDA	1 (07.69)
Angelfish (<i>Pterophyllum scalare</i>)	Tail and fin rot	**1 (07.69)	**1 (07.69)
	White-spot or ich	**1 (07.69)	**1 (07.69)
	Fish louse	NDA	2 (15.38)
Shubunkin variety (<i>Carassius auratus</i>)	Tail and fin rot	**1 (07.69)	**1 (07.69)
Goldfish (<i>Carassius auratus</i>)	Tail and fin rot	2 (15.38)	2 (15.38)
	White eyes	NDA	2 (15.38)
	Skin ulcer	2 (15.38)	2 (15.38)
	Fish TB	**1 (07.69)	**1 (07.69)
	Red blotch	NDA	1 (07.69)
	White-spot or ich	**5 (38.46)	**5 (38.46)
	Anchor worm	2 (15.38)	2 (15.38)
	Fish louse	NDA	2 (15.38)
	White string poop	NDA	1 (07.69)
	Bloat	1 (07.69)	3 (23.08)
	Dropsy	2 (15.38)	NDA
	Pine cone dropsy	NDA	3 (23.08)
	Swim bladder disease	3 (23.08)	NDA
	Zebrafish (<i>Danio rerio</i>)	Spinal deformities	1 (07.69)
Platy (<i>Xiphophorus maculatus</i>)	Pine cone dropsy	NDA	1 (07.69)
Guppy (<i>Poecilla reticulata</i>)	Tail and fin rot	**1 (07.69)	**1 (07.69)
	White eyes	**1 (07.69)	**1 (07.69)
	White-spot or ich	1 (07.69)	2 (15.38)
	Anchor worm	**2 (15.38)	**2 (15.38)
	White string poop	NDA	1 (07.69)
	Bloat	1 (07.69)	2 (15.38)
	Spinal deformities	1 (07.69)	2 (15.38)
Molly (<i>Poecilla sphenops</i>)	Tail and fin rot	**1 (07.69)	**1 (07.69)
	Red blotch	NDA	1 (07.69)
	Anchor worm	**1 (07.69)	**1 (07.69)
	Dropsy	2 (15.38)	NDA
*Hammerhead shark (<i>Pangasius</i> sp.)	White-spot or ich	**1 (07.69)	**1 (07.69)

3.3 Treatments and preventive measures

Out of 13 respondents, only seven were capable to treat some of the identified diseases using mixed natural treatments such as a salt bath with water exchange or temperature adjustments to cure the diseases that infect

the fish. Others used some treatments available online such as API MELAFIX, API PIMAFIX, PowerOut and some commercial drug remedies such as methylene blue and malachite green (Table 3).

TABLE 3 Treatments and preventive measures employed by respondents ($n = 7$) that encountered diseases in ornamental fishes. LY, lymphocytes; TFR, tail and fin rot; WE, white eyes; SU, skin ulcer; FT, Fish tuberculosis; RB, red blotches; SA, saprolegnia; WS-I, white-spot or ich; AW, anchor worm; FL, fish louse; WSP, white stringy poop; BL, bloat; DR, dropsy; SD, spinal deformities; PCD, pine cone dropsy; SBD, swim bladder disease; SCS, slime coat syndrome. (*) asterisk represents the same respondent.

Treatments and preventive measures	Diseases with external symptoms																
	LY	TFR	WE	SU	FT	RB	SA	WS-I	AW	FL	WSP	BL	DR	SD	PCD	SBD	SCS
Natural treatments																	
Salt bath only	✓	-	-	-	-	-	-	-	✓	-	-	-	-	-	-	✓	-
Rock salt (directly rubbed on the ulcer for 8 days; now fully recovered)	-	-	-	✓	-	-	-	-	-	-	-	-	-	-	-	-	-
Isolate, salt bath and water change	-	-	-	-	✓	-	-	-	-	-	-	✓	-	-	-	-	-
Daily 10% water change	-	✓*	✓*	-	-	-	-	✓*	✓*	✓*	-	✓*	-	✓*	-	-	-
50% water change and salt bath	-	✓	-	-	-	-	-	✓	-	-	✓	-	-	-	-	-	✓
Daily water exchange and change of diet	-	✓	-	-	-	-	-	-	-	-	-	-	-	-	-	-	-
Rock salt diluted with the water and raising the water temperature using an aquarium heater and daily water changes	-	-	-	-	-	-	-	✓	-	-	-	-	-	-	-	-	-
Salt bath then lower water depth and aeration near the fish's body or mouth	-	-	-	-	-	-	-	-	-	-	-	-	-	-	-	✓	-
Salt bath and less food	-	-	-	-	-	-	-	-	-	-	-	✓	-	-	-	-	-
Fasting for 24 hours	-	-	-	-	-	-	-	-	-	-	-	✓	-	-	-	-	-
Stop feeding for one week	-	-	-	-	-	-	-	-	-	-	-	✓	-	-	-	-	-
Heater only	-	-	-	-	-	-	-	✓	-	-	-	-	-	-	-	-	-
Treatments available online																	
Can be prevented by putting a daily dose of API MELAFIX 5 ml per 10 gallons of water	-	✓*	✓*	-	-	-	-	✓*	✓*	✓*	-	-	✓*	-	✓*	-	-
Treated with API PIMAFIX and MELAFIX for 3 days (fish got better after)	-	-	-	-	-	-	✓	-	-	-	-	✓	-	-	-	-	-
PowerOut (after 2 days the disease is gone)	-	✓	-	-	-	-	-	✓	-	-	-	-	-	-	-	-	-
Commercial drugs treatments																	
Methylene blue and malachite green	-	-	-	-	-	✓	-	-	-	-	-	-	-	-	-	-	-
Salt bath and methylene blue	-	✓	-	✓	-	-	-	✓	✓	-	-	-	-	-	-	-	-
Salt and malachite green	-	-	-	-	-	-	-	✓	-	-	-	-	-	-	-	-	-
Others																	
Did not treated as it was thought to be a normal disease produced by inbreeding	-	-	-	-	-	-	-	-	-	-	-	-	-	✓	-	-	-
Frequency	1	5	1	2	1	1	1	7	3	1	1	3	3	1	1	2	1

Although not all treatments and preventive measures have feedback on their effectiveness, the results of this study signify that the seven fish owners have some knowledge of fishkeeping. The freshwater ornamental fish sector in PPC just recently became popular as a source of alternative income during the pandemic (Plasus *et al.* 2022). This was also supported by most of the respondents with only 2-year experience in fish keeping (Table 1). Hence, most of the fish owners in PPC have no

appropriate knowledge and skills in terms of fish health management and mostly rely on the information on the internet and other platform like YouTube. Furthermore, unlike in other provinces in the Philippines where the freshwater ornamental fish sector is monitored and assisted by the Bureau of Fisheries and Aquatic Resources (BFAR) as it contributes to the overall fisheries production of the country in terms of value (see Muyot *et al.* 2019), this fishery sector in Palawan has less concern and no

support coming from BFAR.

Natural treatments involving salt or non-iodised salt solution are known as an effective natural treatment for many fish diseases (Illes 2007; Sanil and Vijayan 2008), such as ich (Sanil and Vijayan 2008; Sharma *et al.* 2012; Miles 2019); tail and fin rot and saprolegnia (Miles 2019); fish lice and abdominal dropsy (Magada and Mercy 2016) and ulcerative skin disease (Illes 2007; Roberts *et al.* 2009). In this study, a fish pet with a suspected skin ulcer was cured after 8 days of rubbing rock salt into an infected area (Table 3). Salt can also be used as a disinfectant for fish gills and can limit the uptake of nitrites (Illes 2009). The effectiveness of this treatment depends on the concentration needed for the particular disease (Illes 2007; Sanil and Vijayan 2008; Roberts *et al.* 2009; Magada and Mercy 2016; Miles 2019). For example, white spot disease can be treated with a 2% saline solution for more than seven days. Illes (2007) mentioned that a 3% saline solution can remove the parasites from the fish by immersing the infected fish in half an hour or less. The saline solution may reverse the osmotic gradient or disrupt the body fluid regulation of the parasites, causing them to become dehydrated (Illes 2007; Miles 2019). However, the use of salt for treatment is not recommended above a concentration of 9 ppt, as most freshwater fish cannot tolerate this concentration, which could result in death (Illes 2007; Aquariumscience 2021).

Medical treatments available online like the API MELAFIX and API PIMAFIX were also used in treating various fish diseases in freshwater ornamental fishes in Puerto Princesa City. API MELAFIX and API PIMAFIX were effective against saprolegnia and bloat disease as claimed by two respondents. According to Apifishcare (2021), API MELAFIX is an all-natural antibacterial treatment against infectious diseases such as open wounds and abrasions, fin and tail rot, cloudy eyes and mouth fungus. Meanwhile, API PIMAFIX is an all-natural antifungal agent derived from West Indian Bay Tree, been proven effective against fungal infections in ornamental fish (Apifishcare 2021). Fungal infections that can be treated with API PIMAFIX include cotton wool-like growth in the mouth and body fungus and redness of the fins and body of the fish. Both API MELAFIX and API PIMAFIX do not interfere with the biological filter; alter the pH or discoloration of aquarium water. The combinations of these treatments can increase efficacy against various fish diseases (Apifishcare 2021). However, this contradicts the findings of Shivappa *et al.* (2015), where API MELAFIX has no bactericidal or inhibitory effects against bacterial diseases. PowerOut brand was also used and effective against ich disease. Currently, the only available information about PowerOut is found on a Facebook platform that is effective against hexamita, white-spot diseases and deworming.

Other respondents also used commercial drugs such as methylene blue and malachite green. Methylene blue

was used for treatment against anchor worms, haemorrhagic septicemia or red spot, skin ulcers and tail and fin rot (Table 3). Methylene blue is a fungicidal drug effective for fungal diseases such as saprolegnia (Lipton 2006; Magada and Mercy 2016; Hoshino *et al.* 2018). It is also used for non-parasitic diseases causing skin lesions in fish (Sanil and Vijayan 2008). However, the use of this treatment is not advisable in cyclic tanks as it may kill the bio-filters therein (Yanong 2003). Meanwhile, malachite green was used against white-spot disease and haemorrhagic septicemia or red blotch (Table 3). Malachite green is an effective and traditional treatment like methylene blue, which is useful as a prophylactic treatment to protect fish eggs from fungal diseases, especially saprolegniasis (Illes 2007; Magada and Mercy 2016; Miles 2019). It is most effective when combined with formalin, which can treat fungal infection and bacterial and protozoan diseases (Lewbart 2001; Lipton 2006; Illes 2007; Sanil and Vijayan 2008; Rao *et al.* 2013). However, there is a need to avoid malachite green because of its carcinogenic properties (Soduva *et al.* 2007; Roberts-Sweeney 2016; Miles 2019). In addition, malachite green is toxic to the fishes in the aquarium at high temperatures and in water with low pH levels (Illes 2007).

Although the diseases identified by 13 respondents infecting the freshwater ornamental fishes did not undergo laboratory analysis, the findings show that the fish hobbyist in Palawan can identify the diseases in their freshwater ornamental fishes. Moreover, seven of the 13 respondents can apply treatments that enable the fish to recover from certain disease attacks. Despite this, appropriate training for fish keeping in PPC is needed as some respondents use commercially available treatments for ornamental fish which have a negative effect on human health and the environment if not properly utilised. Capacitating the local ornamental fish breeders to apply proper care and responsible handling of diseases in ornamental fish could lead to the improvement of fish produced and promotion of this industry in the whole province of Palawan. In addition, there is a need to conduct a clinical evaluation of the effectiveness of some treatments suggested by fish owners and various social media platforms against other diseases.

SUPPORTING INFORMATION

Additional supporting information may be found in the online version of the article at the publisher's website. Visit <https://doi.org/10.17017/j.fish.485> for details.

ACKNOWLEDGEMENTS

The time and participation of all fish owners are greatly acknowledged. Thanks to Migz Mojagan for his support during the survey and to Vanessa Abrea and Jennie Cleto for their assistance during the conduct of the study. Thanks are also extended to the two anonymous review-

ers for providing critical comments and suggestions to improve this manuscript.

CONFLICT OF INTEREST

The author declares no conflict of interest.

AUTHORS' CONTRIBUTION

NJMFM – Conceptualisation, Writing -original draft, review and editing, Data Curation, Investigation, Methodology, Validation; **MMGP** – Supervision, Writing -review and editing, Visualisation, Methodology, Validation.

DATA AVAILABILITY STATEMENT

The data that support the findings of this study are available on a reasonable request from the corresponding author.

REFERENCES

- Alderton D (2008) Encyclopedia of aquarium and pond fish. Dorling Kindersley Limited, Great Britain. 403 pp.
- Apifishcare (2021) API MELAFIX and PRIMAFIX. <http://apifishcare.com>. Accessed on 2 February 2021.
- Aquariumscience (2021) The science of aquariums. <http://aquariumscience.org>. Accessed on 2 February 2021.
- Bassleer G (2017) Optimal health care for ornamental fish. *INFOFISH International*. pp. 42–45.
- Cardoso P, Moreno A, Moreno L, de Oliveira C, Baroni F, ... Balian S (2019) [Infectious diseases in aquarium ornamental pet fish: prevention and control measures](#). *Brazilian Journal of Veterinary Research and Animal Science* 56: e151697.
- Clements H, Valentin S, Jenkins N, Rankin J, Baker JS, ... Sloman K (2019) [The effects of interacting with fish in aquariums on human health and well-being: a systematic review](#). *Plos One* 14(7): e0220524.
- Faruk M, Hasan M, Anka I, Parvin M (2012) Trade and health issues of ornamental fishes in Bangladesh. *Bangladesh Journal of Progressive Science and Technology* 10: 163–168.
- Galib SM, Imam MA, Rahman MA, Mohsin ABM, Fahad MFH, Chaki N (2013) A study on aquarium fish business in Jessore district, Bangladesh. *Trends in Fisheries Research* 2(3): 11–14.
- Galib SM, Mohsin ABM (2010) Exotic ornamental fishes of Bangladesh. *Bangladesh Journal of Progressive Science and Technology* 8(2): 255–258.
- Hoshino E, Hoshino M, Tavares-Dias M (2018) Parasites of ornamental fish commercialized in Macapá, Amapá State (Brazil). *Brazilian Journal of Veterinary Parasitology* 27: 75–80.
- Illes BD (2007) Tropical freshwater fish aquariums. eBookwholesaler, Kew Victoria, Australia. 102 pp.
- Lewbart GA (2001) Bacteria and ornamental fish. *Seminars in Avian and Exotic Pet Medicine* 10(1): 48–56.
- Lipton AP (2006) Diseases of ornamental fishes and their control. *International Seminar on Ornamental Fish Breeding, Farming and Trade*. Central Marine Fisheries Research Institute, Kochi, India. pp. 109–114.
- Livengood E, Chapman F (2007) The ornamental fish trade: an introduction with perspectives for responsible aquarium fish ownership. University of Florida. IFAS Extension. 8 pp.
- Magada S, Mercy T (2016) Health management in ornamental fish farming. In: Jain A, Saini V, Kaur V (Eds) *Best management practices for freshwater ornamental fish production*. National Fisheries Development Board, Ministry of Agriculture and Farmer's Welfare, GOI, Hyderabad, India. pp. 94–106
- Miles S (2019) Common conditions in freshwater aquarium fish. *Veterinary Practice Today* 7(6): 52–55.
- Miller-Morgan TJ, Heidel JR (2010) Biosecurity and ornamental fish (pp. 71–88). In: Roberts HE (Ed) *Fundamentals of ornamental fish health*. Wiley-Blackwell Publishing, Iowa, USA.
- Muyot F, Mutia MT, Manejar AJ, Guirhem G, Muñoz M (2019) [Status of ornamental fish industry in the Philippines: prospects for development](#). *The Philippine Journal of Fisheries* 26(2): 82–97.
- Nair S, Vidhya V, Gopukumar S (2020) Importance of optimum water quality indices in successful ornamental fish culture practices. *Parishodh Journal* 9(2): 516–531.
- Nanayakkara NP, Sandaruwan KPL, Kumara WAAU, Rathnasuriya MIG (2021) [Impacts of COVID-19 pandemic on ornamental fish supply chain in Sri Lanka](#). *Asian Fisheries Science* 34: 243–252.
- OATA (2006) Biosecurity and the ornamental fish industry: future proofing the industry. *Ornamental Aquatic Trade Association*, Westbury, UK. 174 pp.
- Plasus MMG, Plasus L, Mecha NJMF (2022) Baseline study on the freshwater ornamental fish industry in Palawan, Philippines. *The Palawan Scientist* 14(1): 11–21.
- Rao VM, Kumar TA, Haq MB (2013) [Diseases in the aquarium fishes: challenges and areas of concern: an overview](#). *International Journal of Environment* 2: 127–146.
- Roberts H (2010) *Fundamentals of ornamental fish health*. Blackwell Publishing, Malaysia. 227 pp.
- Roberts HE, Palmeiro B, Weber ES (2009) Bacterial and parasitic diseases of pet fish. *Veterinary Clinician of Northern America: Exotic Animal Practice* 12(3): 609–638.
- Roberts-Sweeney HE (2016) Anatomy and disorders of the oral cavity of ornamental fish. *Veterinary Clinician of North America: Exotic Animal Practice* 19: 669–687.
- Saba AO, Ismail A, Zulkifli SZ, Shohaimi S, Azmai MNA

(2021) [Economic contribution and attitude towards alien freshwater ornamental fishes of pet store owners in Klang Valley, Malaysia](#). PeerJ 9: e10643.

Sanil N, Vijayan K (2008) Diseases in ornamental fishes. In: Kurup BM, Boopendranath M, Ravindrana K, Banu S, Nair A (Eds) Ornamental fish breeding, farming and trade. Department of Fisheries. Government of Kerala, India. pp. 175–186.

Sharma M, Shrivastav A, Sahni Y, Pandey G (2012) Overviews of the treatment and control of common fish diseases. International Research Journal of Pharmacy 3(7): 123–127.

Shivappa RB, Christian LS, Noga EJ, Law JM (2015) Laboratory evaluation of safety and efficacy for MELAFIX (*Melaleuca cajuputi* extracts). Journal of Exotic Pet Medicine 24: 188–192.

Sudova E, Machova J, Svobodova Z, Vesely T (2007) Negative effects of malachite green and possibilities of its replacement in the treatment of fish eggs and fish: a review. Veterinarni Medicina 52(12): 527–539.

Walczak N, Puk K, Guz L (2017) [Bacterial flora associated with diseased freshwater ornamental fish](#). Journal of Veterinary Research 61(4): 445–449.

Watson CA, Shireman JV (2002) Production of ornamental aquarium fish. University of Florida. IFAS Extension. 4 pp.

Yanong RPE (2003) Fish health management considerations in recirculating aquaculture systems—part 2: pathogens. University of Florida. IFAS Extension. 9 pp.



NJMF Mecha  <https://orcid.org/0000-0002-3885-5413>

MM Gonzales-Plasus  <https://orcid.org/0000-0003-4556-4056>